



BC Cancer Agency

CARE + RESEARCH

An agency of the Provincial Health Services Authority

VARIETY: THE SPICE OF LIFE



Cancer Screening + Diversity Needs

- Core Materials: Brochures, Posters, and so on
- Specialized Materials
- Activities and Plans



BC Cancer Agency

CARE + RESEARCH

An agency of the Provincial Health Services Authority

Screening Mammography (SMP) - Core Materials

Brochures



Posters

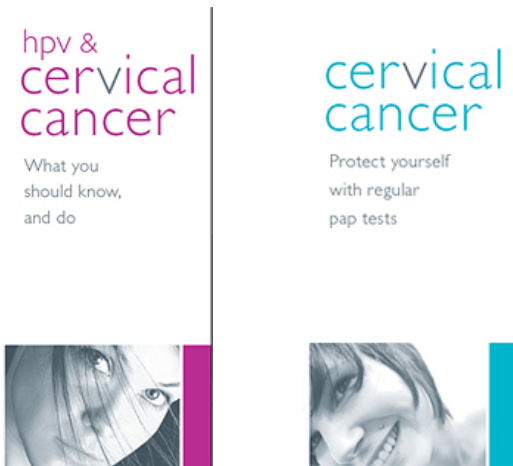


Appointment Pads




Cervical Cancer Screening (CCSP) - Core Materials

Brochures



Booklets



Physician-based promotion

Order Form

Please FAX to: 604-660-3645

Brochures (general distribution)

Cervical cancer (blue) _____ 25 _____ 50
HPV & cervical cancer (pink) _____ 25 _____ 50

Booklets (limited distribution)

Preventing cervical cancer (orange) _____ 5 _____ 10
Abnormal pap smear (green) _____ 5 _____ 10

Please note: Booklets are for a physician to use with a patient for further discussions.

Instructional DVD or Video (please circle)

Speculum Exam & Pap Smear _____ (number)

Laminated Card

Technique for Obtaining Cervical Smears _____ (number)

Send to:

Name: _____

Address: _____

Postal Code: _____

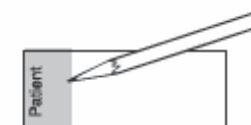
Pap Smear Technique

SLIDE LABELING IS MANDATORY

On the frosted end of the slide using a lead pencil, print patient's surname (include at least the first 7 letters), must be legible, spelled correctly and match the name on the requisition.

A major cause of a false negative cervical smear is failure of the smear collector to sample the transformation zone (squamocolumnar junction).

The transformation zone is the region lying between the columnar epithelium of the endocervix and the



matte squamous epithelium of the ectocervix. It is here that carcinogens act upon the squamous metaplastic cells of the transformation zone to cause squamous dysplasia and squamous carcinoma.

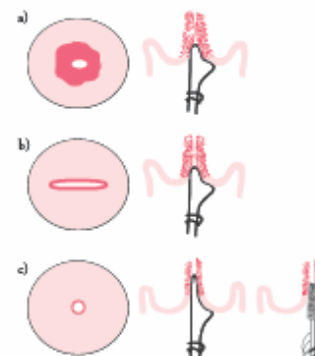
Generally during the reproductive years, the transformation zone lies on the ectocervix. Post-menopausally, it recedes within the endocervix.

SINGLE SLIDE METHOD

Please use the single slide method. Multiple slides from one patient are neither necessary nor cost effective. Patients with a double cervix are the obvious exception.

If two sites are sampled, i.e. cervix and endocervix, they can be applied to two different areas of the same side of the slide.

VARIATIONS IN CERVICAL TRANSFORMATION ZONE

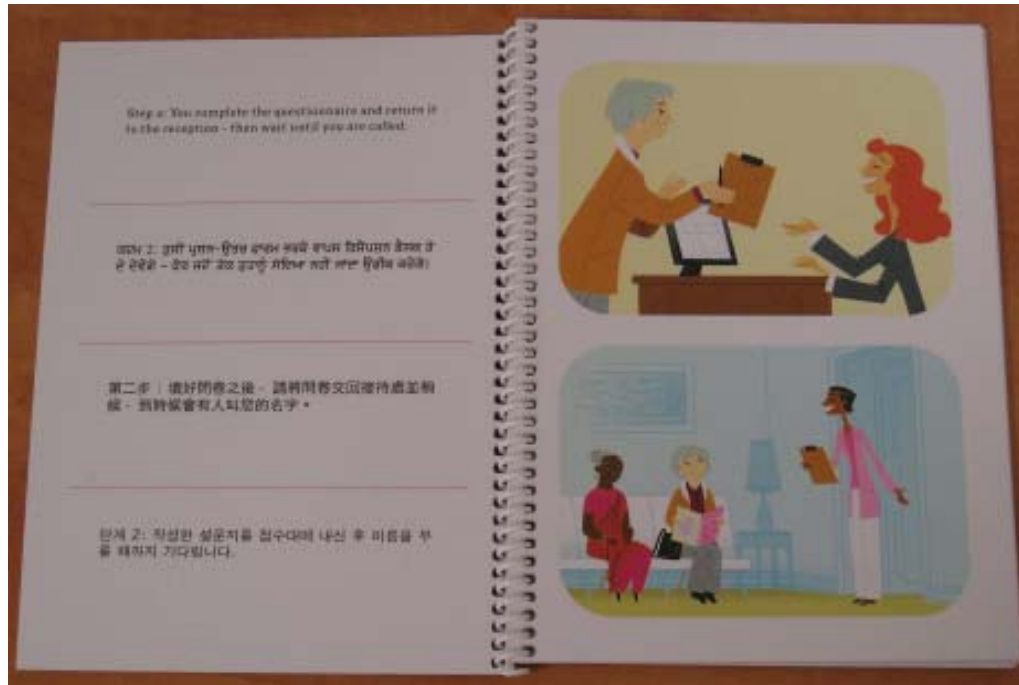

The location of the squamocolumnar junction is dependent on the patient's age, parity, hormonal status and any previous surgery. If squamocolumnar junction is visible, sample with a spatula. If not visible, i.e. in the canal, sample with elongated end of spatula or cytobrush.

- a) Reproductive age group, nulligravida; squamocolumnar junction often visible on ectocervix lateral to os. Os (small, round or oval). Sample with spatula.
- b) Reproductive age group, parous; squamocolumnar junction often at or near external os. Sample with spatula.
- c) Post menopausal. Squamocolumnar junction often in canal. Cervical os often smaller. Sample with elongated end of spatula and cytobrush.

SMP Educational Materials

Step-by-Step Guide: Having a Mammogram



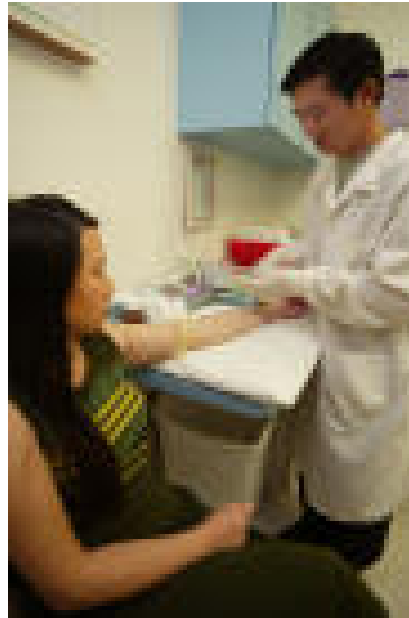
Multi-lingual CD LANGUAGES

- English
- Punjabi
- Chinese
- Korean

Plans and Activities



Build network with health care professionals, community workers & leaders



Regularly visit Health fairs, workshops and seminars, and places of worship, FN communities, etc.

First Nations Campaign: Circle of Strength



Storybook
illustrated by FN
artist



Postcard to maintain
health



Network with
Community & Health
Workers

Circle of Strength: First Nations Campaign con't



Transport women from First Nations communities to fix or mobile services

Wrap-up & Questions

- Materials developed with diverse groups in mind
- Number of plans and activities to build a stronger network
- Modifying current materials and developing new materials

Ann McCulloch: 604-877-6000 ex. 4622

Ann MacDonald: 604-707-5927